

# Caso Clínico

## 24 de abril 2012.

### ACCN

Dr. Alejandro Vargas Román  
Neurocirujano-Neuroendovascular

# Caso Clínico

- Paciente femenina y vecina de Turrialba.
- 19 años.
- Post parto 2 meses.
- Conocida sana.
- APQx: 1 cesárea.
- Crisis convulsiva tónico clónica generalizada

# Posibles diagnósticos

- ??????????

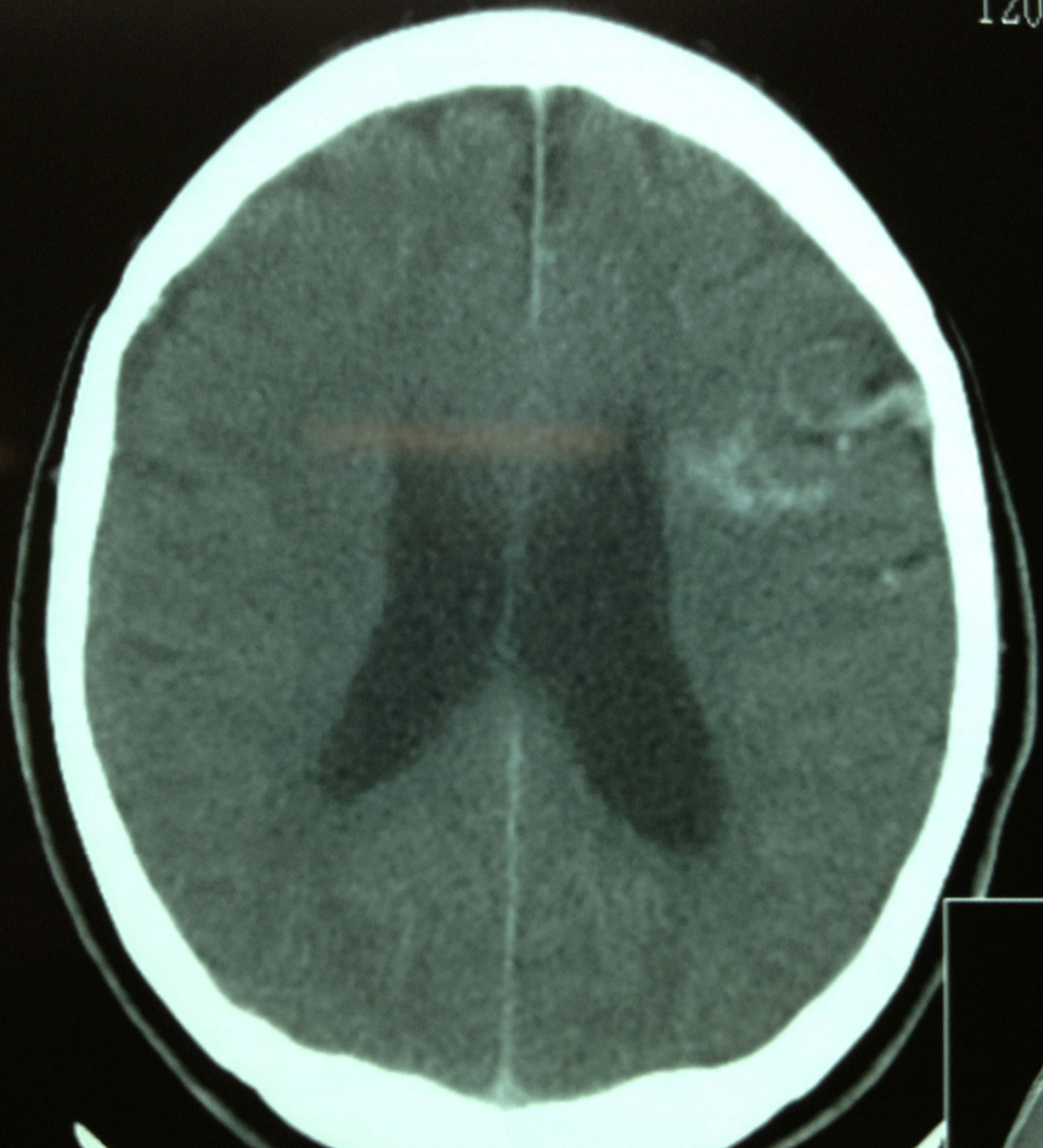
- ??????????

- ??????????

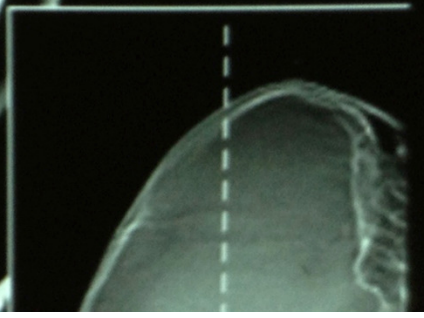
- ??????????.

27/02  
+65.0mm  
+0.0D

120kV/180mAs  
/F  
HCT  
+3.0mm/r  
INTERP-1



R



WT = 40

Z/CE  
+75.0mm  
+0.0D

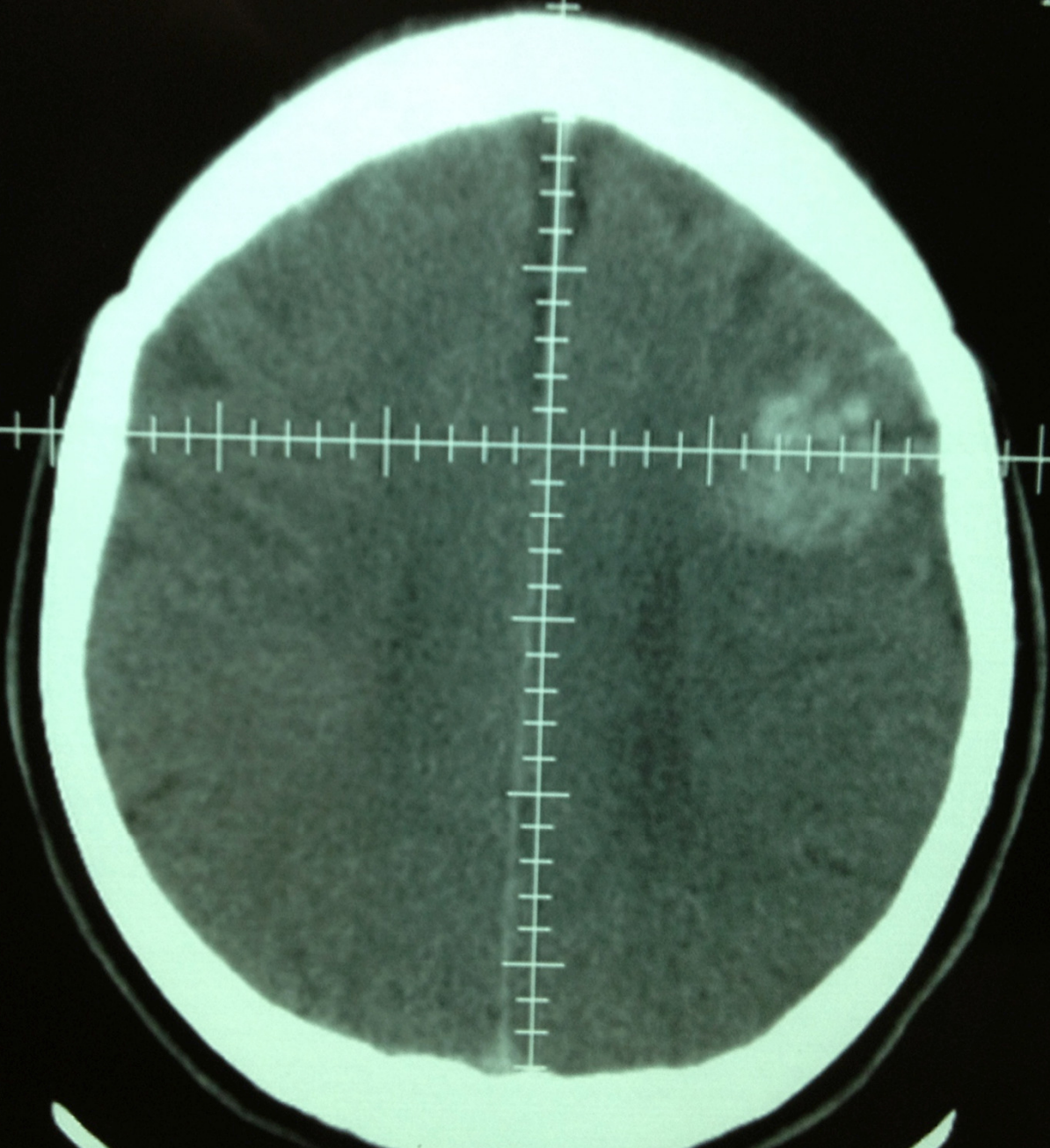
12.04.04 14:21:40.0  
120kV/180mAs

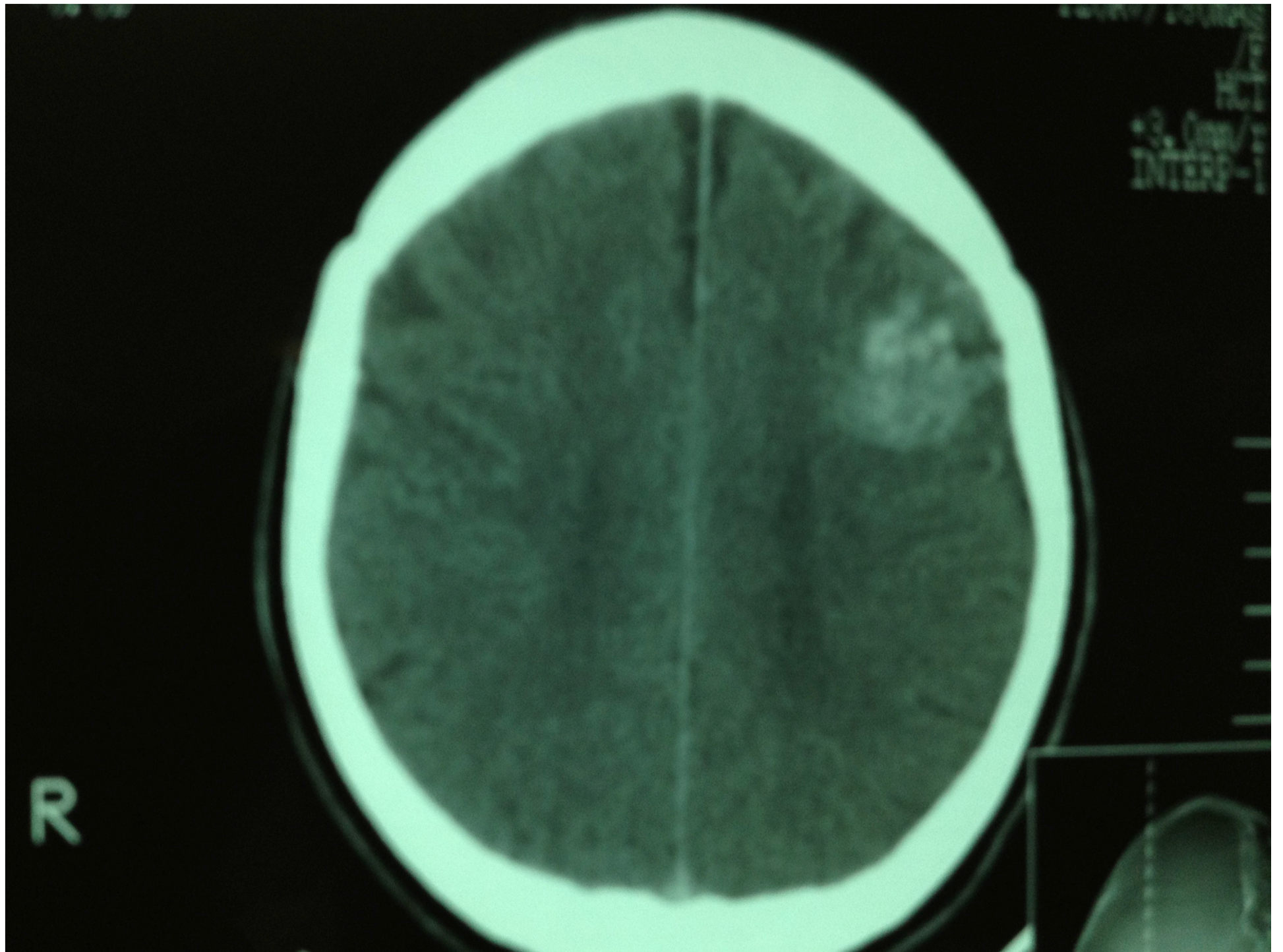
/F  
HCT  
+3.0mm/r  
INTERP-1



R  
5 mm  
(261, 181)  
0.0

37 A





# Arteriografía cerebral

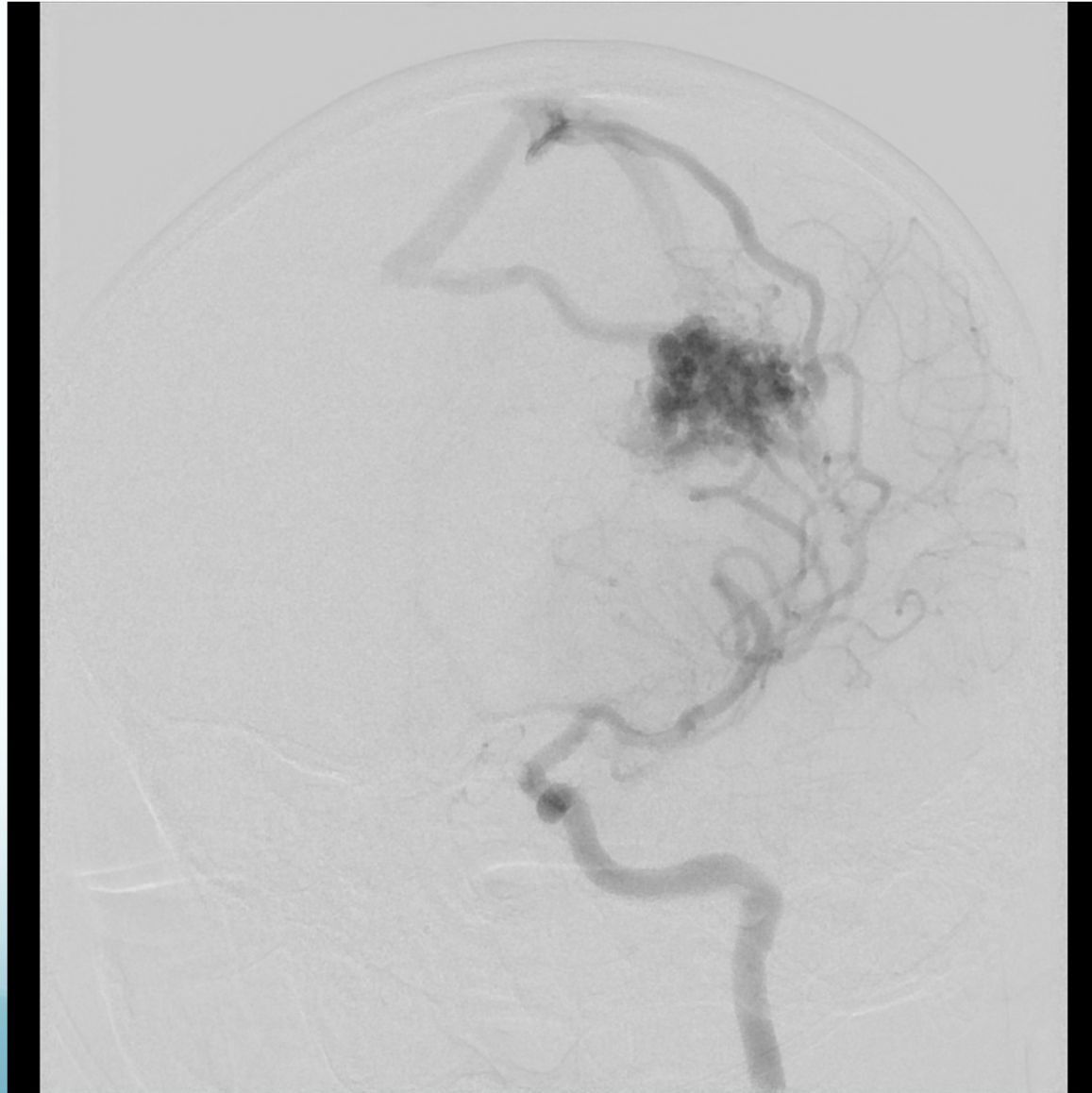


Image size: 1024 x 1024

Ellis Bonilla Raquel I-001063934 ( 19 y , 19 y )


View size: 542 x 541

Care Carotid - Care Carotid

WL: 2047 WW: 4095

1

10



4094

2047

-0



Zoom: 53% Angle: 0

Im: 4/4

Uncompressed

Position: HFS



24/04/12 12:57:14

Made In OsiriX



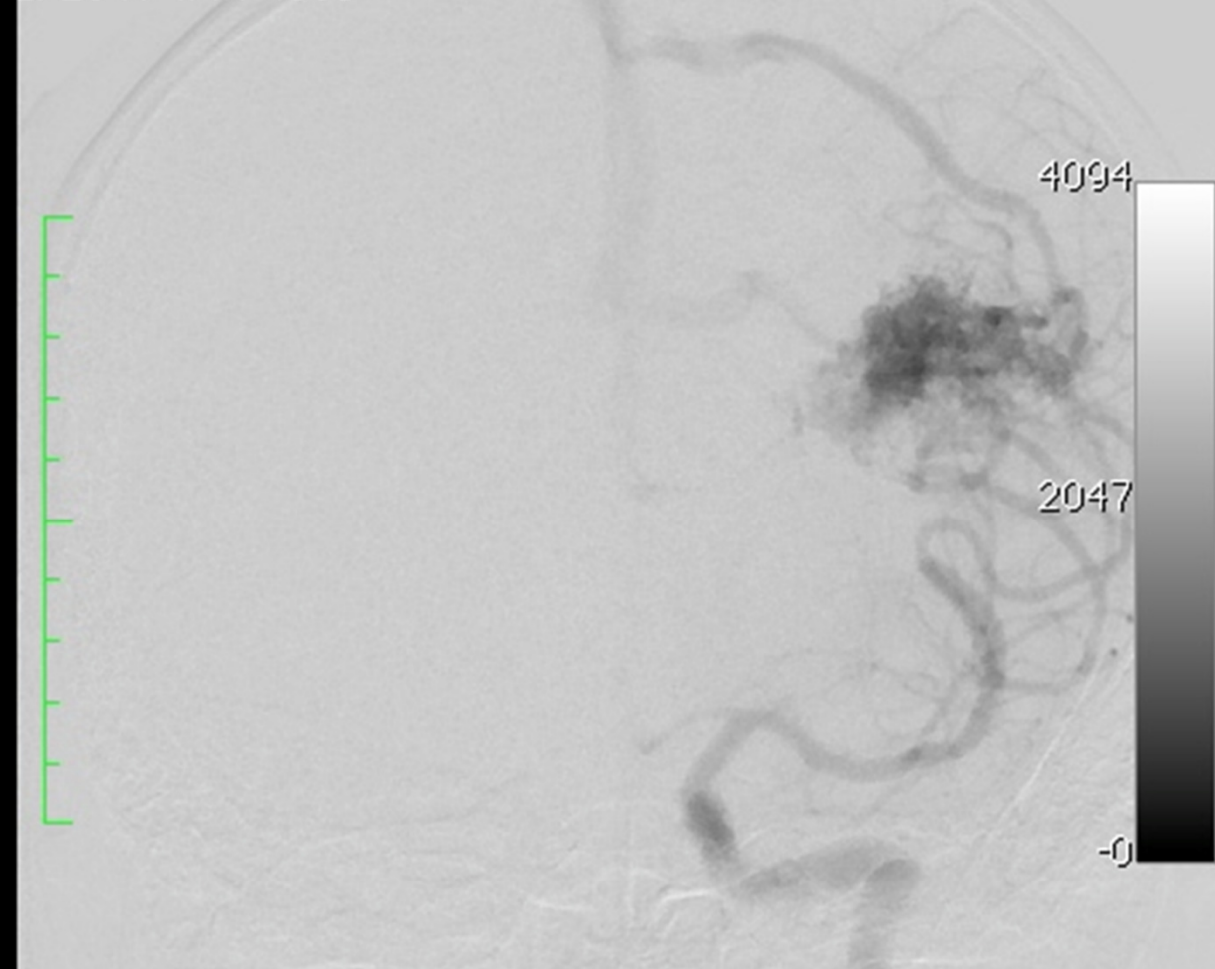
Image size: 1024 x 1024-Ellis Bonilla Raquel F001063934 ( 19 y , 19 y )

View size: 504 x 504

Care Carotid — Care Carotid

WL: 2047 WW: 4095

1  
8



Zoom: 49% Angle: 0

Im: 1/1

Uncompressed

Position: HFS

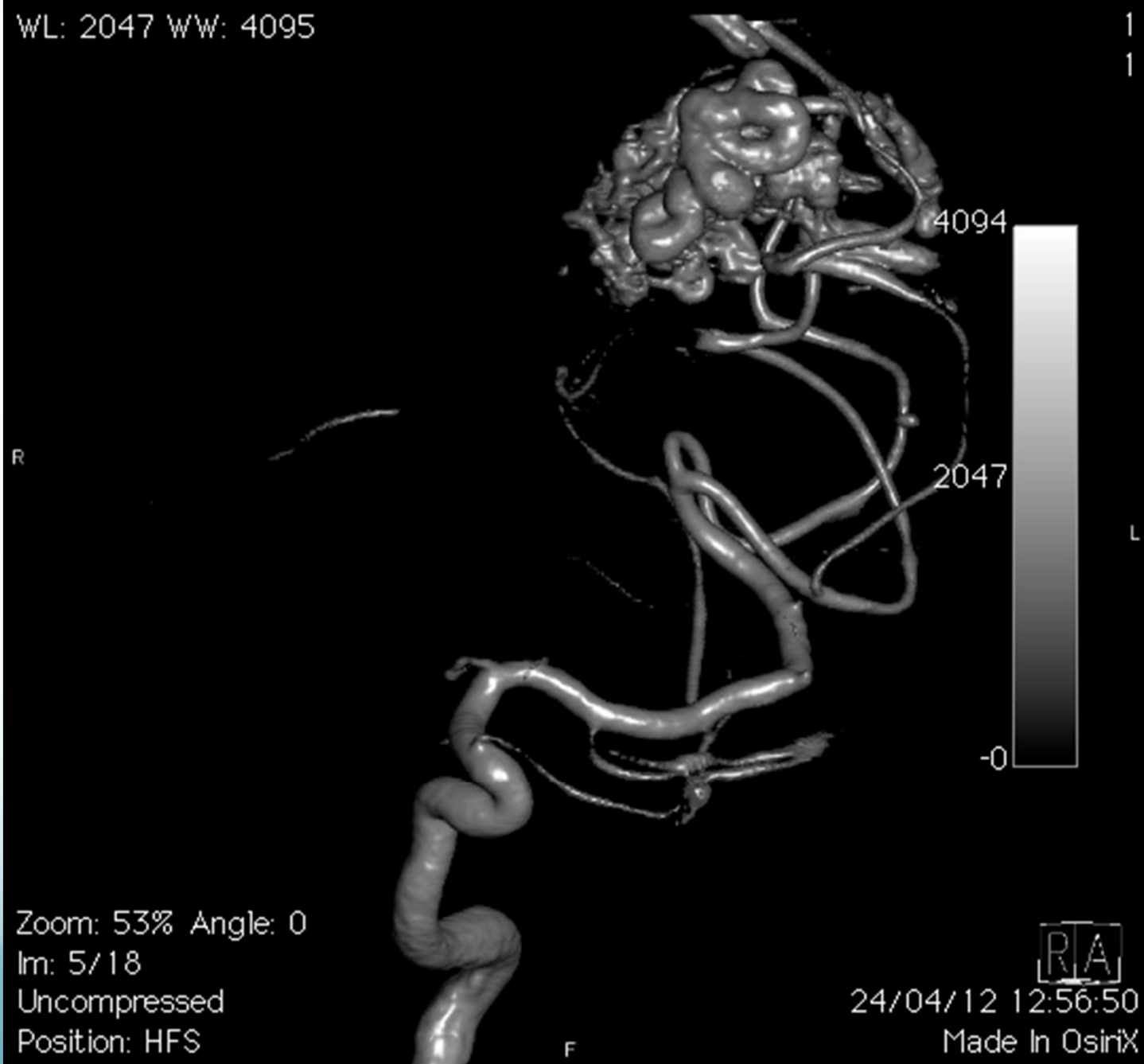
24/04/12 12:57:37

Made In OsiriX



Image size: 1024 x 1024  
View size: 541 x 541  
WL: 2047 WW: 4095

Ellis Bonilla Raquel I-001063934 ( 19 y 19 y )  
-- Series for iPilot Reference



Zoom: 53% Angle: 0  
Im: 5/18  
Uncompressed  
Position: HFS

24/04/12 12:56:50  
Made In OsiriX

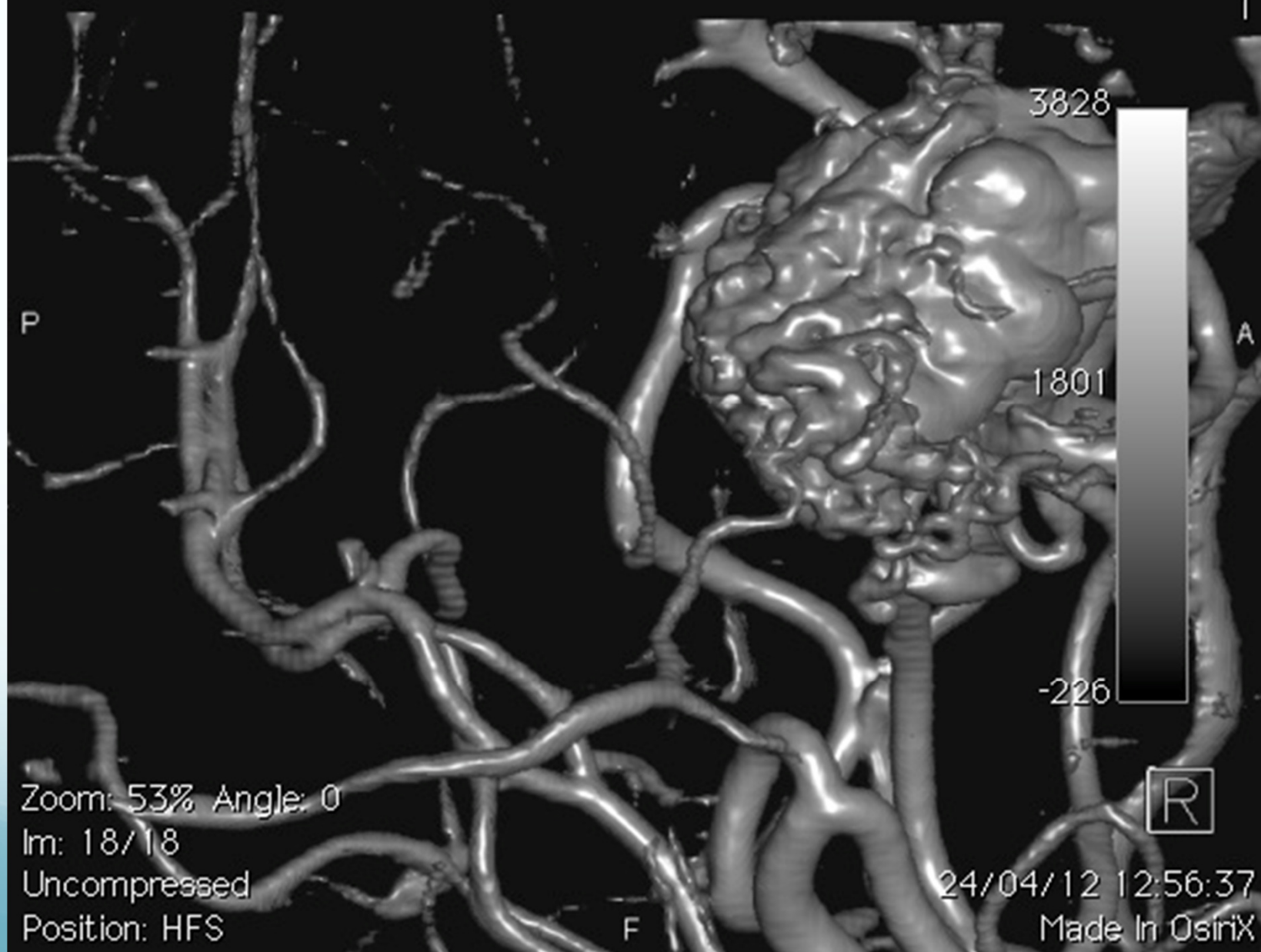
Image size: 1024 x 1024

Ellis Bonilla Raquel I-001063934 ( 19 y , 19 y )

View size: 541 x 476

-- Series for iPilot Reference

WL: 1801 WW: 4054



Zoom: 53% Angle: 0

Im: 18/18

Uncompressed

Position: HFS

24/04/12 12:56:37

Made In OsiriX

Image size: 1024 x 1024

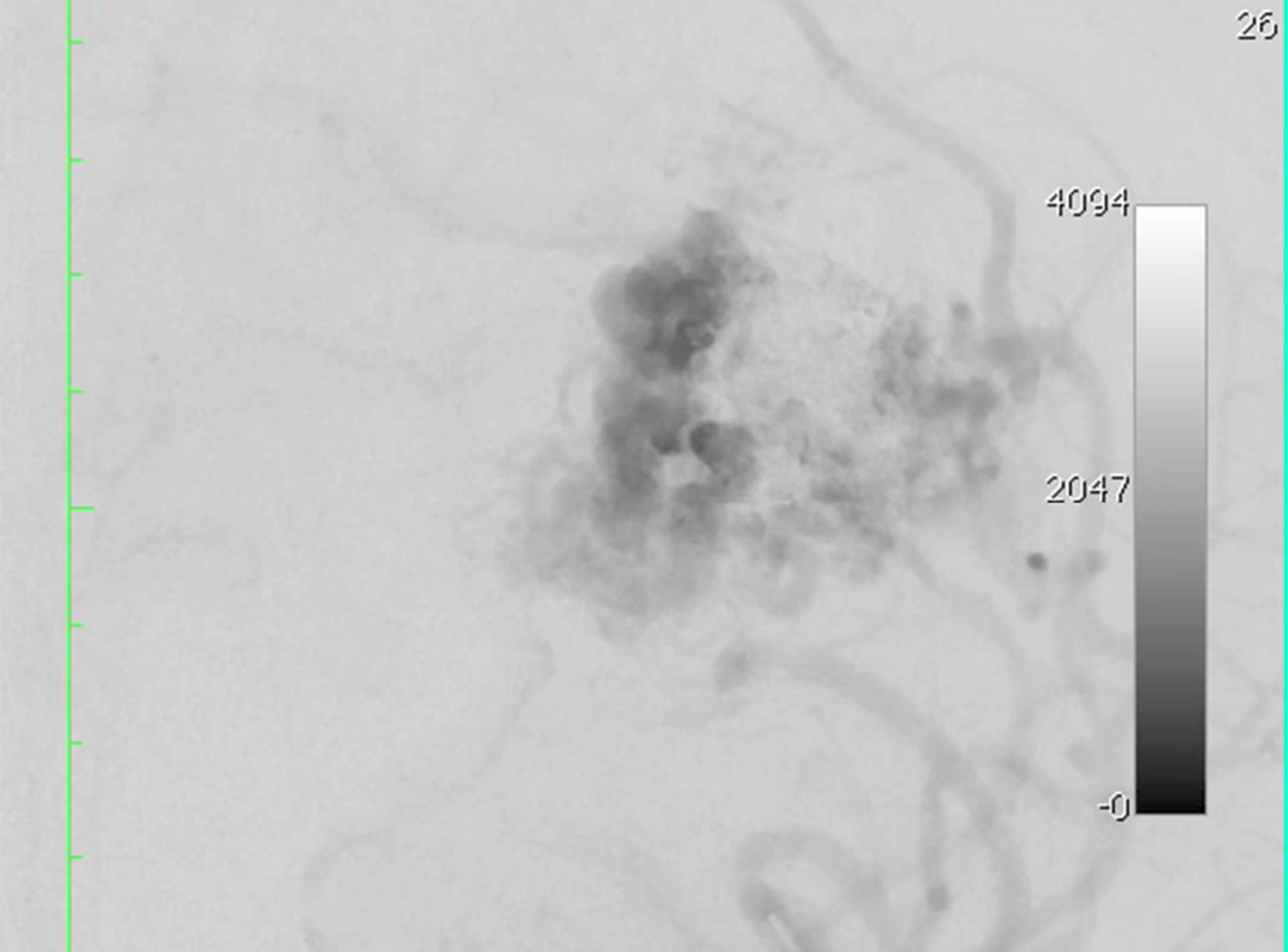
Ellis Borilla Raquel F001063934 ( 19 y , 19 y )

View size: 541 x 541

Care Carotid — Care Carotid

WL: 2047 WW: 4095

1  
26



Zoom: 53% Angle: 0

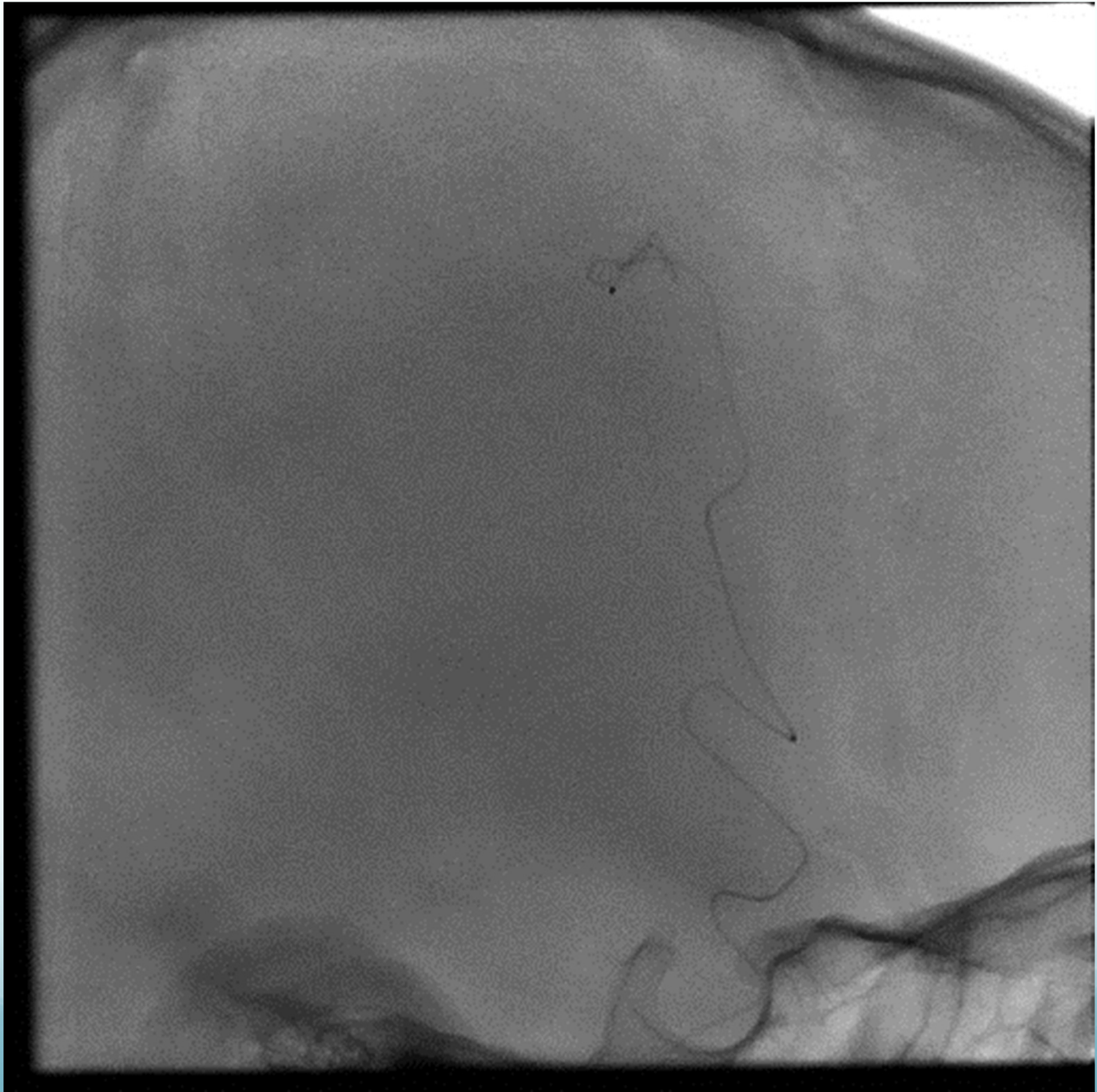
Im: 17/28

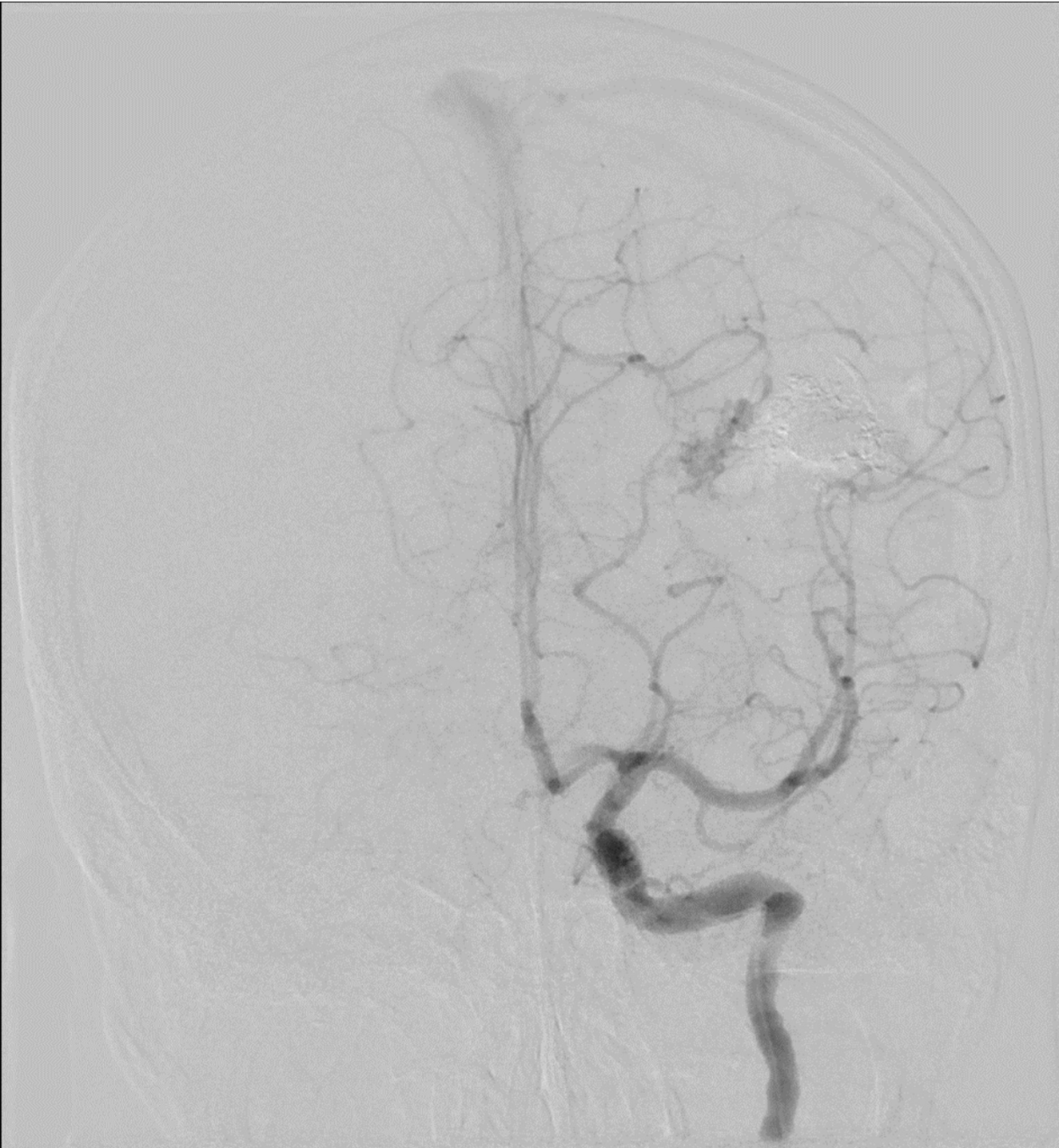
Uncompressed

Position: HFS

24/04/12 12:55:53

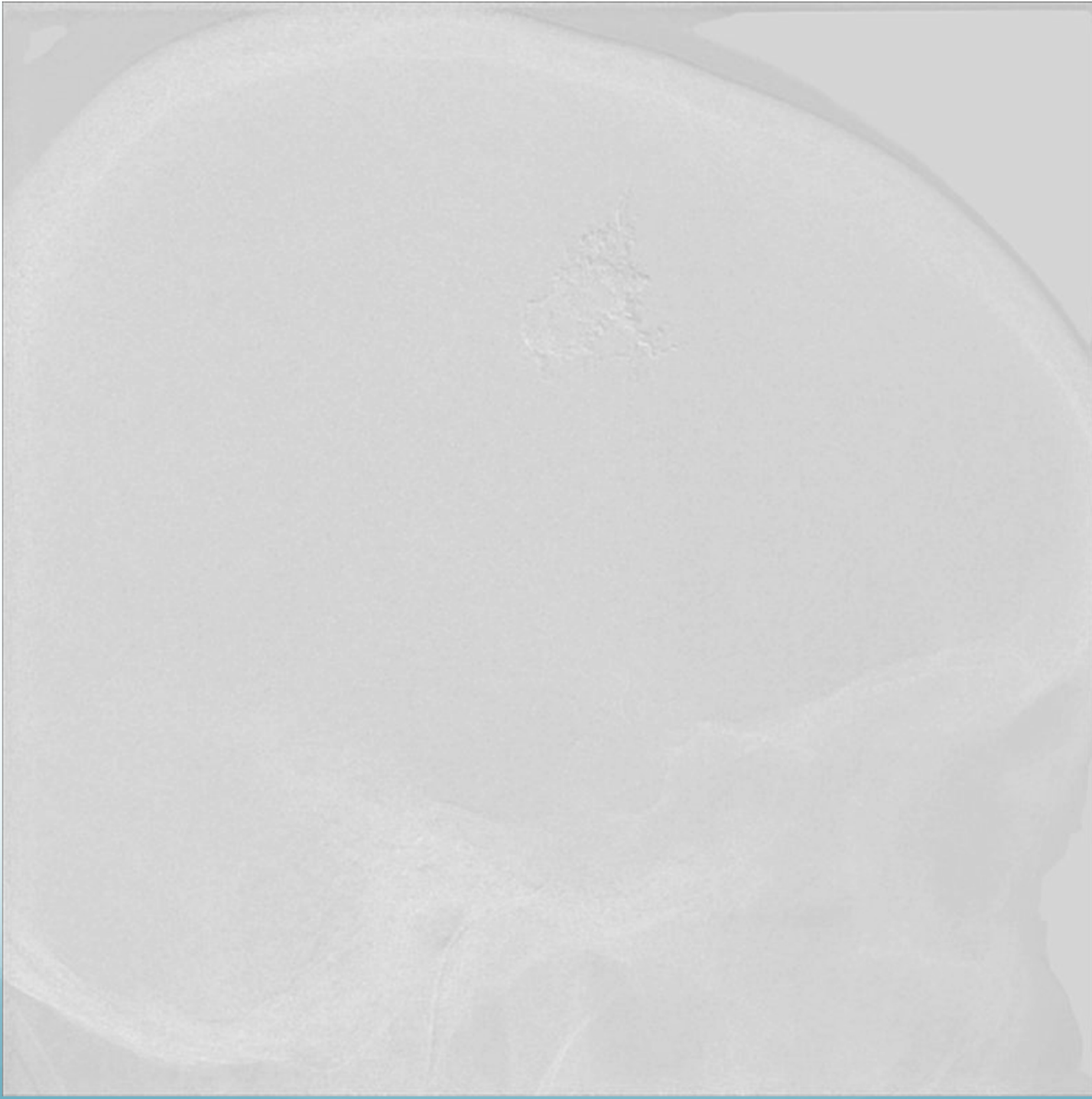
Made In OsiriX



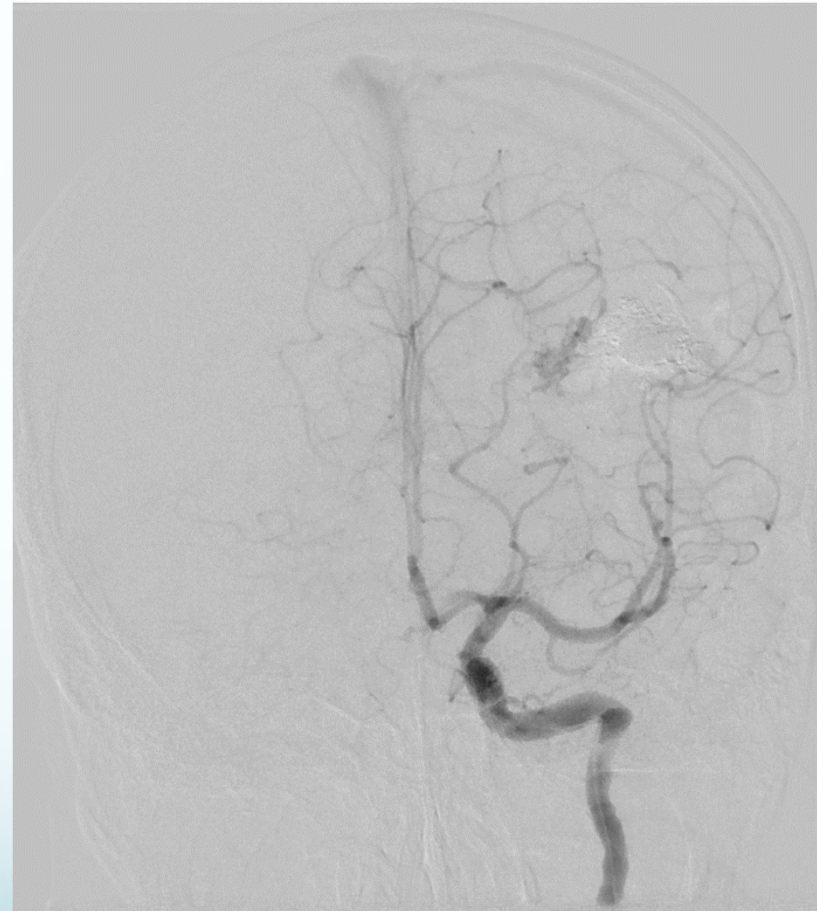
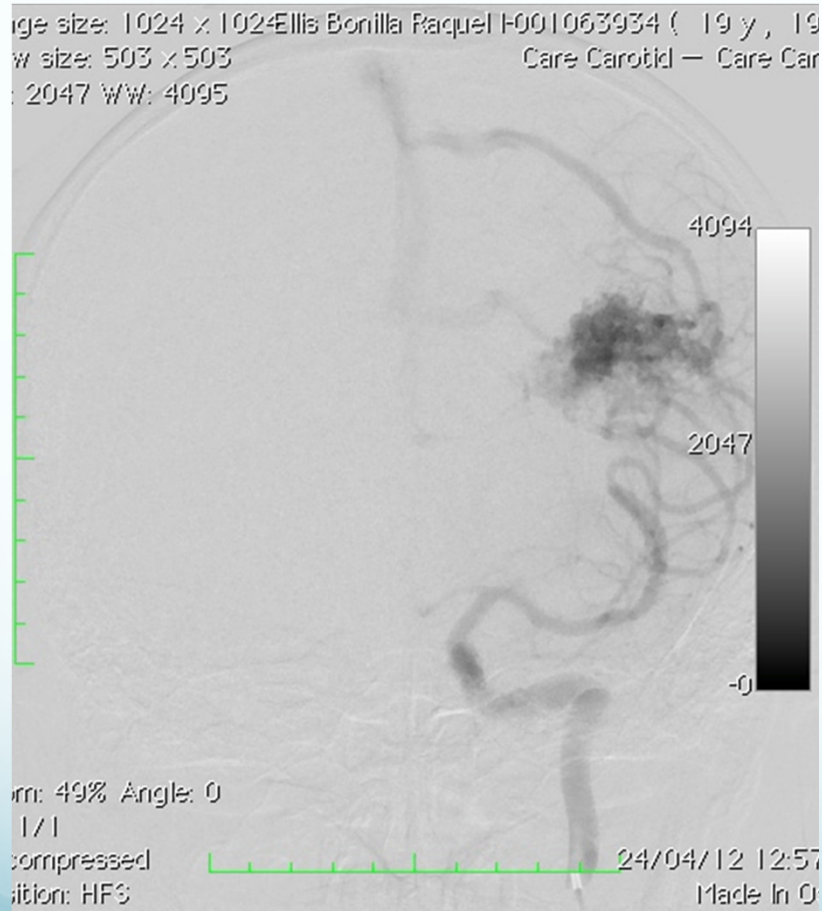




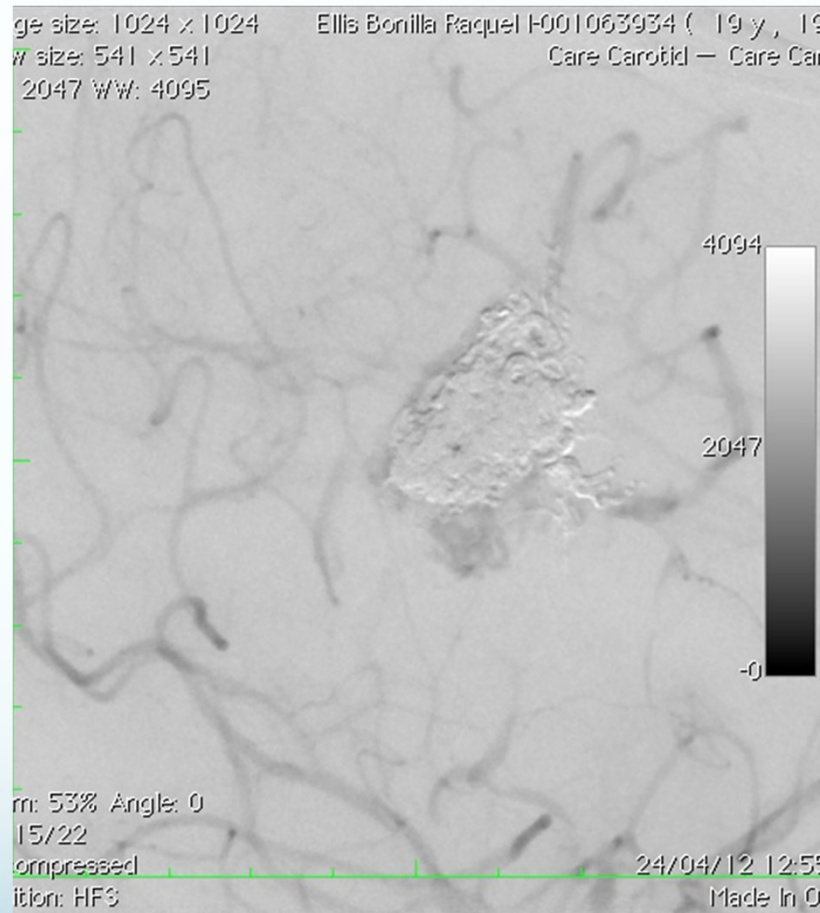
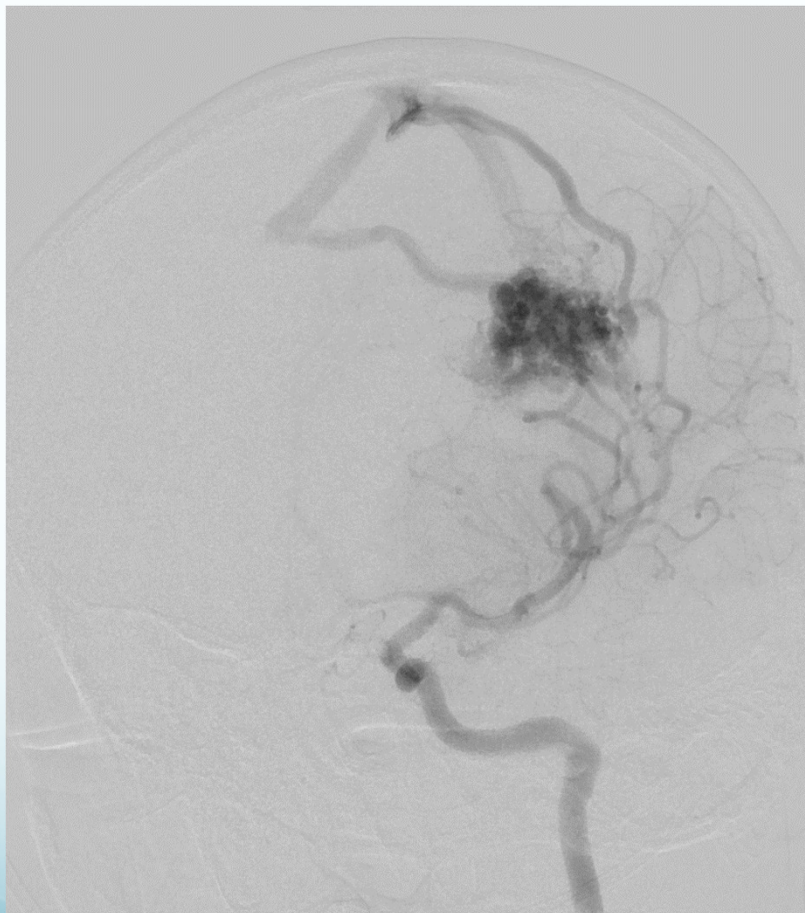




# Incidencia AP



# Oblicua carótida interna izda.



# Lateral

